

Brain CT Scan, Sonography and EEG Findings in Neonates with Seizure

How to Cite This Article: Mussavi M, Khanzadeh SH, Sadeghvand SH¹, Hasanpour E, Akbari M, Nasiri SH, Valaei F. Brain CT Scan, Sonography and EEG Findings in Neonates with Seizure. *Iran J Child Neurol.* summer 2022; 16(3): 183-191

Mirhadi MUSSAVI MD¹
Shokoufeh KHANZADEH MD²,
Shahram SADEGHVAND MD³,
Eslam HASANPOUR MD⁴,
Morteza AKBARI MD⁵,
Shahram NASIRI MD⁶,
Fateme VALAEI MD⁷

1. Department of Pediatrics,
Pediatric Health Researches
Center, Faculty of Medicine,
Tabriz University of Medical
Sciences, Tabriz, Iran

2. Student Research
Committee, Tabriz University
of Medical Sciences, Tabriz,
Iran

3. Clinical Research
Development Unit of Children
Hospital, Tabriz University of
Medical Sciences, Tabriz, Iran

4. Clinical Research
Development Unit of Children
Hospital, Tabriz University of
Medical Sciences, Tabriz, Iran

5. Immunology Research
Center, Tabriz University of
Medical Sciences, Tabriz, Iran

6. Department of Pediatric
Neurology, Abuzar Children's
Medical Center, Ahvaz
Jundishapur University of

Abstract

Objectives

This study aimed to determine the frequency of different types, causes, and abnormal findings of brain computed tomography scan (CT scan) and ultrasonography (US) and multichannel- electroencephalography (EEG) in neonates with seizure. The ability of brain CT scan was also compared with US in terms of detecting the underlying causes of neonatal seizures.

Materials & Methods

In this cross-sectional retrospective study, the medical records of 90 neonates younger than 28 days with the definite diagnosis of seizure were reviewed. The data were analyzed using SPSS 22 through descriptive and Exact fisher tests.

Results

Totally, 90 newborns (M: F = 1.5:1) with mean age of 63.11 ± 32.8 days were enrolled. 35.5% of newborns were born before the 37th week of pregnancy. In this study, 45.6% of EEG findings, 22% of brain CT scan findings, and 12.5% of US findings were abnormal. The automatisms (38.9%) and benign idiopathic neonatal seizure (70.7%) were the most common seizure type and cause respectively. The hypoxic Ischemic encephalopathy was the most common abnormal finding (30%) in brain CT scan.

Conclusions

Given the accuracy of EEG in detection of brain pathologies, where available, all neonatal seizures should be initially confirmed using EEG. Radiologic investigations (CT scan, US) off the head/ cranium

Medical Sciences, Ahvaz, Iran
7. Clinical Research
Development Unit of
Children Hospital, Tabriz
University of Medical
Sciences, Tabriz, Iran.

Corresponding Author

Sadeghvand SH. MD
Pediatric Neurologist,
Department of Pediatrics,
Tabriz University of Medical
Sciences, Tabriz, Iran
Email: Shahram.
sadeghvand@yahoo.com

Received: 20-May -2021

Accepted: 30-May -2022

published:16- Jul-2022

Introduction

Seizure is defined as a transient occurrence of signs or/and symptoms as a result of aberrant synchronous or excessive activity of the brain neurons. Seizure is the most prevalent neurological emergency in neonates that occurs in 1 - 5 per 1000 live births. The neonatal seizures often are symptomatic of a disease with a suspected or documented underlying etiology (1, 2). Common etiologies in neonatal seizure are hypoxic-ischemic encephalopathy (HIE), genetic disorders, metabolic disorders (hypocalcemia/ hypoglycemia), infection, and stroke. In addition, sometimes they are idiopathic (benign idiopathic neonatal seizure) (3, 4). The gold standard test for seizure diagnosis is multichannel – electroencephalography (EEG) (5). Indeed, EEG helps us to avoid both overdiagnosis

should be done to detect the cause of neonatal seizure. The capacity of brain CT scan to detect underlying causes of neonatal seizures is more than US.

Keywords: Seizures; Ultrasonography; Electroencephalography; Neonates; Computed Tomography

DOI: 10.22037/ijcn.v17i1.34950

and underdiagnosis of neonatal seizures (6). In addition, it is notable that this tool is not limited to the mere seizure diagnosis; it provides the data required for a detailed investigation of the background activities and some special features and patterns/waves indicative of the nervous system development (7). Moreover, radiologic investigations like ultrasonography (US) and computed tomography (CT) scan of the brain have a central role in neonatal seizure assessment (8-10). The US may be a helpful initial imaging tool for the term and preterm-born neonatal brain. The ease and portability of US makes it a fast initial assessment tool of neonates with seizures (11, 12). It allows detection of hydrocephalus, intraventricular hemorrhage, and white matter disease like cystic periventricular leukomalacia, particularly in very preterm patients with a gestation age of < 32 weeks (13). The CT scan has a specific but limited role in the assessment of neonatal seizures (14, 15). It is quick and does not need sedation; it can provide better assessment of the brain in comparison with US in cases in which acute stroke or hemorrhage is suspected (16). The World Health Organization's (WHO) guideline on neonatal seizures declared that despite the great clinical significance of this disease, many aspects of its diagnosis and management are not well established by evidence-based studies (17). This project provides a significant opportunity to advance the understanding of

neonatal seizures by investigating the frequency of different types, causes, and findings of brain CT Scans, US, and EEG in neonates with seizures. In addition, the capability of brain CT scan and US to detect underlying causes of neonatal seizures was compared. The study was carried out at Farmanfarmayan Hospital, Tabriz, Iran.

Materials & Methods

In this retrospective cross-sectional study, we reviewed the medical records of all neonates aged one 1 - 28 days with a diagnosis of seizure. The subjects had been admitted to the Neonatal Intensive Care Unit (NICU) of Farmanfarmayan Children's Hospital (Tabriz, Iran), a tertiary care center. The study was carried out in two years' period from April 2017 to March 2019.

The inclusion criterion was newborns with a definite diagnosis of seizure by a pediatric neurologist. The exclusion criteria were as follows: (i) seizure-like syndromes (ii) neonates who underwent neither brain imaging nor EEG.

Totally, 90 patients were selected. A structured questionnaire was designed to record sex, age, birth weight, birth length, birth head circumference, gestational age, delivery details (C-section or normal vaginal delivery and hypoxia during delivery), seizure type (clonic, tonic, myoclonic, automatisms), causes of the seizure (hemorrhage, hypocalcemia, hypoglycemia, benign idiopathic neonatal seizure, HIE), history of neonatal jaundice, family history of epilepsy, CT scan findings (brain hemorrhage, hypoxic-ischemic lesions, brain edema, other findings) US findings (normal or abnormal) according to a certified radiologist report and EEG findings (normal or abnormal). Hypocalcemia was defined as serum calcium level < 7.5 mg/dL. Blood sugar levels < 35 mg/dL or 1.9

mmol/L during 1 to 3 hours of life; < 40 mg/dL or 2.2mmol/L during 3 to 24 hours of life; and < 45 mg/dL or 2.5 mmol/L after 24 hours of life were considered as low.

To make sure of consistency in data collection, the data were collected by a medical student (H.E.) who was completely trained and audited by the principal researcher (M.M.).

Neonatal seizures were defined as the presence of automatisms, myoclonic, clonic and tonic attacks according to Kellaway and Mizrahi criteria (12) in 1 to 28 day-old patients. Neonatal seizures were diagnosed clinically by a neonatologist (M.M.). All neonates underwent brain C.T. scan, U.S. and multichannel-EEG. Spiral brain C.T. scan without IV contrast was performed using 16-slice C.T. scan Siemens. Ultrasonography was performed using a 3.5 - 5 MHz curved probe. All ultrasonographic examinations were performed from the anterior fontanelle by a single radiologist without any knowledge of other findings. All patients underwent 12 channel 20-min standard clinical surface EEG. The EEG signals were filtered by a second-order band-pass Butterworth filter with 0.1 to 30 Hz cut-off frequencies and a sensitivity of 10. Brain oscillatory activity was determined through inspection of EEG tracings by one practiced neurologist (S.S.), initially blinded to CT scan and U.S. findings. As a part of routine examinations, glucose and electrolyte testing were also performed.

Statistical Analyzes

The data were analyzed using the SPSS version 22.0 for Windows. Continuous variables were expressed as mean \pm standard deviation (S.D.) and categorical variables as number (percentage).

The Fisher Exact test was used to determine

the correlation between C.T. scan findings and demographic data of the patients

A P-value < 0.05 was considered statistically significant.

Our study was approved by the Ethical Committee, Tabriz University of Medical Sciences (ethical code of I.R.TBZMED.REC.1398.869).

Results

The medical records of 90 infants with seizures who met the inclusion criteria were reviewed. Mean age, birth length, and birth head circumference were 63.11 ± 32.8 days, 50.15 ± 21.30 cm, and 35.90 ± 23.70 cm respectively. The mean birth weight was 3161.30 ± 620.72 gram, and 13 cases (14.4%) were low birth weight (LBW) with mean birth weight of < 2500 gram. Totally, 54 cases (60%) were male, and the male: female ratio was 1.5:1. The mean gestational age was 37.6 weeks, and 32 cases (35.5%) were preterm (gestational age < 37 weeks). In addition, 36 neonates (40%) were born through normal vaginal deliveries and 54 neonates (60%) through C-sections. Positive history of hypoxia during delivery was found in six cases (6.7%), a history of neonatal jaundice was found in five cases (5.6%), and a family history of seizure was found in six cases (6.7%).

3.1. Types of Seizures

Totally, 35 cases (38.9%) had automatisms, 26 cases (28.9%) had clonic seizure, 23 cases (25.6%) had

tonic seizure and six cases (6.7%) had myoclonic seizure.

3.2. Causes of Seizures

Totally, 63 seizures (70%) were due to benign idiopathic neonatal seizure, 19 cases (21.1%) were due to hypoxemic-ischemic encephalopathy (HIE), four cases (4.4%) were due to brain hemorrhage, two cases (2.2%) were due to hypoglycemia, and two cases (2.2%) were due to hypocalcemia. Therefore, the benign idiopathic neonatal seizure was the most common cause of neonatal seizures.

3.3. Abnormal EEG/CT/US Findings

Figure 1 shows the rate of abnormal findings in CT, EEG, and US in neonatal seizure. The US was abnormal in 12.5%. In 41 (45.6%) neonates, multichannel-EEG had abnormal findings including abnormal background activities in 29 (32.2 %) cases and epileptiform activities in 12 (13.2 %) cases. The CT scan results were abnormal in 20 cases (22.2%), including six cases (6.7%) of hypoxemic-ischemic lesions, five cases (5.6%) of brain hemorrhage, four cases (4.4%) of brain edema, and five cases (5.6%) of other findings (cephalohematoma, vascular ectasia, encephalomalacia, caput Succedaneum, ventriculomegaly). There was not any statistically significant correlation between CT scan findings and demographic variables (Table 1). All neonates with abnormalities in US had an abnormal CT scan, too.

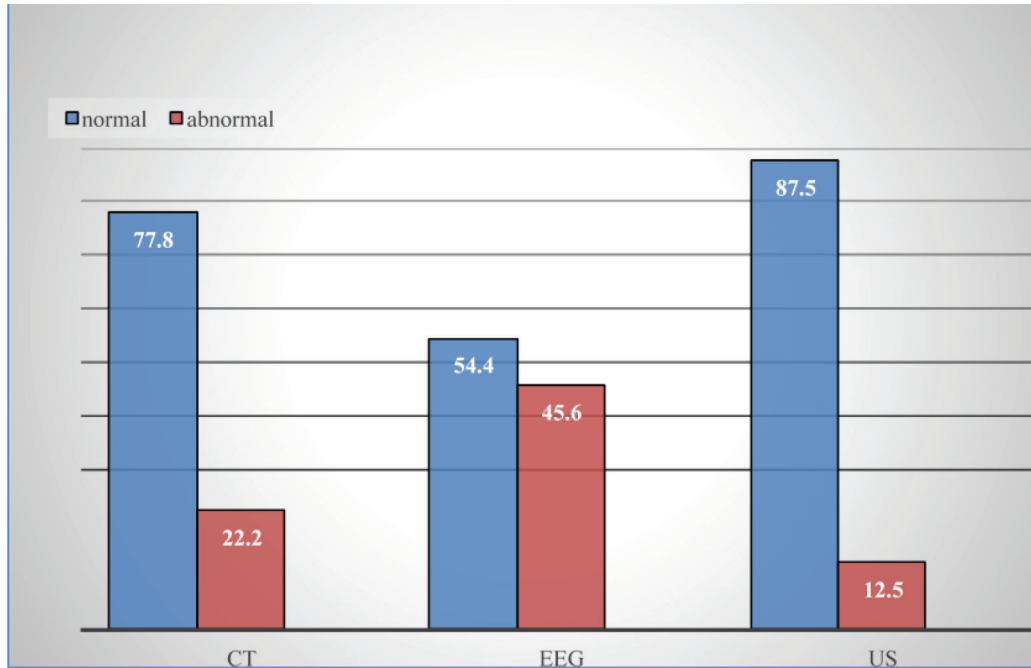


Figure 1. Rate of abnormal findings in CT, EEG and US in neonatal seizure

Table 1. Correlation Between CT Scan Findings and Demographic Variables in Neonatal Seizure a, b

Variable	Age (days)		Gestational Age (mo)		Birth Weight (gr)		Family History of Seizure	
	≤ 3	> 3	< 37	≥ 37	< 2500	≥ 2500	Positive	Negative
CT Scan								
Normal	18 (20.0)	52 (57.8)	23 (25.6)	47 (52.2)	8 (8.8)	62 (68.9)	5 (5.6)	64 (71.1)
Abnormal	8 (8.8)	12 (13.4)	9 (10.0)	11 (12.2)	5 (5.6)	15 (16.7)	1 (1.1)	19 (21.1)
Total	26 (28.8)	64 (71.2)	32 (35.6)	58 (64.4)	13 (14.4)	77 (85.6)	6 (6.7)	84 (93.3)
P-value	NS		NS		NS		NS	

^a Abbreviation: NS, non-significant.

^b Data are presented as No. (%).

Discussion

Similar to the findings of previous studies (8, 18) The current study has shown that the majority of patients were male. Indeed, the male gender is considered a risk factor for seizures during the neonatal period (18). Consistent with Vanikim (19), 85.6 % of patients weighed > 2500 grams in our study. Another study in Iran revealed that 76% of neonates weighed > 2500 grams (8). This result showed that seizures could be more common

in heavier neonates.

4.1. Causes of Seizures

Similar to Salehiomran et al. (20) and notwithstanding laboratory radiological and clinical examinations, the majority of seizures in our study were idiopathic. This is inconsistent with previous studies reporting HIE as the most common cause of neonatal seizures (8, 21). The HIE was the second cause (21.1%) of neonatal seizures in our study. It may be due to the study

population characteristics. It has been shown that the age of onset of HIE in neonates was within the first 24 hours of birth, while in our study, the mean age of neonates was 63.11 ± 32.8 days. With regard to the study population age, it is not surprising that HIE was seen in the fewer percentage of neonates in our study than that of other studies.

In this study, both metabolic disorders and brain hemorrhage were considered as the third reason for seizures with four cases (4.4%) in the both groups. In a similar study conducted in Iran on 141 neonates with seizures, metabolic disorders were the second cause with 31 neonates (22%), and brain hemorrhage was the fourth cause with 11 neonates (7.8%) in neonatal seizure (8).

4.2. Types of Seizures

In the present study, the most common type of seizure was automatism (38.9%), followed by clonic (28.9%), tonic (25.6%), and myoclonic (6.7%). Similar results were reported by Alyasiri (22) and Marzoki (23), but this was different from Najeeb et al. (24) and Ahmadabadi et al. (9) studies in which clonic seizures were the most prevalent cause. This difference in the type of seizures in several studies could be due to the statistical population.

4.3. Abnormal EEG/CT/US Findings

With respect to the brain CT scan examinations, it was found that 22.2% of patients had abnormal findings. A comparison of our results to the findings of previous studies revealed that all studies reported that HIE was the most prevalent abnormality in CT scan results. In Ahmadabadi et al. study, CT findings in 41.4% of the neonates showed abnormalities, of which 44.8% were HIE (9). In another study conducted in Iran, CT findings in 33.3% of the neonates showed abnormalities, of which 47% were HIE (8). HIE occurs in one

to three per 1000 live full-term births. Of affected newborns, 15%–20% of affected newborns will die in the postnatal period, and an additional 25% will develop severe and permanent neuropsychological sequelae, including mental retardation, visual motor or visual perceptive dysfunction, increased hyperactivity, cerebral palsy, and epilepsy. It has been shown that the outcomes of HIE are permanent and devastating; so it is a noticeable burden for the neonate, the parents, and society (25, 26).

Accordingly, using CT scan tests, HIE can be diagnosed earlier; and by following a suitable treatment, the survival rate of neonates can be improved.

In a study by Nabavi et al. conducted from 2010 to 2011 to assess brain US findings in neonatal seizure, 48.5% of the US examinations had abnormal findings. They introduced US as an appropriate non-invasive tool for timely detection of cerebral causes of neonatal seizures (12). In our study, although the number of US examinations with abnormal findings was lower than the figure shown in the mentioned study, 12.5% prevalence of abnormal US findings was also noticeable. In a study by Mercuri et al., 69% of neonates with seizure had abnormal lesions in their head US results (27). Although the number of CT scans and EEG examinations with abnormal findings was higher than the figure reported by US, these tests are not available everywhere, especially in third world societies, and require specific conditions like immobilization. Therefore, it seems that US is an available, affordable, safe, and bedside screening technique that can be of significant help for medical doctors (12, 28).

In our study, 45.6% of patients had abnormal EEG. The rate of abnormal EEGs in Salehiomran et al. (20) was 14.3%. Therefore, the number of

EEGs with abnormal findings was higher than the figure reported in US and CT scan. That is, EEG is the most accurate tool for confirming a sign or symptom is of epileptic origin. On the other hand, while performing EEG, special conditions need to be considered, including an interpretation of EEG trace by a trained expert, minimal skills training of EEG technicians, and minimum acceptable standards for the facility and equipment. In addition, our study showed that EEG in some neonates with seizures was normal. Therefore, it seems that the standard and proper method of diagnosing neonatal seizures is clinical checks (17).

Several limitations of our study need to be considered. First, the small sample size and retrospective method are notable as methodological shortcomings. Second, video-EEG polygraphy and MRI findings were not included in this study. In conclusion, given the accuracy of EEG to detect brain pathologies, where available, all neonatal seizures should be initially confirmed by EEG. Radiologic investigations (US, CT scan) of the head/ cranium are not recommended for evaluating the absence or presence of clinical seizures in neonates. These tools are recommended mostly to detect the cause of neonatal seizure.

Acknowledgment

The authors are grateful to the Clinical Research Development Unit of Children Hospital Tabriz University of Medical Sciences for their contribution to this study.

Our study was approved by the Ethical Committee, Tabriz University of Medical Sciences (ethical code of I.R.TBZMED.REC.1398.869).

Author's Contribution

Conceptualization: M.M. and SH.KH.; methodology: S.S.; investigation: E.H.; resources: M.M. and S.S.; software: SH.KH.; formal analysis: SH.KH.; data curation: M.M.; writing original draft preparation: SH.KH.; writing review and editing: SH.KH., M.M. and S.S.; supervision: M.M. and S.S.; project administration: M.M. and S.S. All authors have read and agreed to the published version of the manuscript.

Conflict of Interest

The authors declare that there is no conflict of interest.

References

1. Olson DM. Neonatal Seizures. *NeoReviews*. 2012;13(4):e213-e23.
2. Kang SK, Kadam SD. Neonatal Seizures: Impact on Neurodevelopmental Outcomes. *Front Pediatr*. 2015;3:101.
3. Pressler RM, Cilio MR, Mizrahi EM, Moshe SL, Nunes ML, Plouin P, et al. The ILAE classification of seizures and the epilepsies: Modification for seizures in the neonate. Position paper by the ILAE Task Force on Neonatal Seizures. *Epilepsia*. 2021;62(3):615-28.
4. Hahn JS, Olson DM. Etiology of Neonatal Seizures. *NeoReviews*. 2004;5(8):e327-e35.
5. Stevenson NJ, Tapani K, Lauronen L, Vanhatalo S. A dataset of neonatal EEG recordings with seizure annotations. *Sci Data*. 2019;6:190039.
6. Tsuchida TN, Wusthoff CJ, Shellhaas RA, Abend NS, Hahn CD, Sullivan JE, et al. American clinical neurophysiology society standardized EEG terminology and categorization for the description of continuous EEG monitoring

- in neonates: report of the American Clinical Neurophysiology Society critical care monitoring committee. *J Clin Neurophysiol.* 2013;30(2):161-73.
7. Pisani F, Pavlidis E. The role of electroencephalogram in neonatal seizure detection. *Expert Rev Neurother.* 2018;18(2):95-100.
 8. Eghbalian F, Rasuli B, Monsef F. Frequency, Causes, and Findings of Brain CT Scans of Neonatal Seizure at Besat Hospital, Hamadan, Iran. *Iran J Child Neurol.* 2015;9(1):56-63.
 9. Ahmadabadi F, Mirzarahimi M, Ahadi A, Alizadeh Z. Frequency, causes, and findings of brain CT scans of neonatal seizure at Ardabil City Hospital, Ardabil, Iran. *Int Surg J.* 2020;7(8):2485-9.
 10. Tekgul H, Gauvreau K, Soul J, Murphy L, Robertson R, Stewart J, et al. The current etiologic profile and neurodevelopmental outcome of seizures in term newborn infants. *Pediatrics.* 2006;117(4):1270-80.
 11. Glass HC, Bonifacio SL, Sullivan J, Rogers E, Ferriero DM, Goldstein R, et al. Magnetic resonance imaging and ultrasound injury in preterm infants with seizures. *J Child Neurol.* 2009;24(9):1105-11.
 12. Nabavi SS, Partovi P. Brain Ultrasonography Findings in Neonatal Seizure; a Cross-sectional Study. *Emerg (Tehran).* 2017;5(1):e41.
 13. Girard N, Raybaud C. Neonates with seizures: what to consider, how to image. *Magn Reson Imaging Clin N Am.* 2011;19(4):685-708; vii.
 14. Weeke LC, Van Rooij LG, Toet MC, Groenendaal F, de Vries LS. Neuroimaging in neonatal seizures. *Epileptic Disord.* 2015;17(1):1-11; quiz
 15. Sivaswamy L. Approach to neonatal seizures. *Clin Pediatr (Phila).* 2012;51(5):415-25.
 16. Glass HC. Neonatal seizures: advances in mechanisms and management. *Clin Perinatol.* 2014;41(1):177-90.
 17. World Health Organization. Guidelines on neonatal seizures. Geneva: World Health Organization; 2011 2011.
 18. Kohelet D, Shochat R, Lusky A, Reichman B, Israel Neonatal N. Risk factors for neonatal seizures in very low birthweight infants: population-based survey. *J Child Neurol.* 2004;19(2):123-8.
 19. Mwaniki M, Mathenge A, Gwer S, Mturi N, Bauni E, Newton CR, et al. Neonatal seizures in a rural Kenyan District Hospital: aetiology, incidence and outcome of hospitalization. *BMC Med.* 2010;8:16.
 20. Salehiomran M, Araby S, Ahmadpour-kacho M, Hajiahmadi M, Jahangir T. Neonatal seizure and short-term outcomes in hospitalized neonates. *Casp J Pediatr.* 2018;4(2):308-12.
 21. Taghdiri MM, Emdadi M, Eghbalian F, Tavasoli AR, Jabari M. [Radioimaging in Convulsion Neonates Based on Brain CT Scan Without Contrast]. *Avicenna J Clin Med.* 2005;11(4):50-4.
 22. Alyasiri AA. Etiology and short outcome of neonatal seizures in Babylon gynecology and pediatrics teaching hospital. *Med Res Chronicles.* 2015;2(1):30-40.
 23. Marzoki JMA. Clinco-Biochemical Profile Of Neonatal Seizures. *QMJ.* 2010;6(10):163-4.
 24. Najeeb S, Qureshi AM, Anis ur R, Ahmad F, Shah S, Khan AY, et al. Aetiology and types of neonatal seizures presenting at Ayub Teaching Hospital Abbottabad. *J Ayub Med Coll Abbottabad.* 2012;24(1):33-7.
 25. Douglas-Escobar M, Weiss MD. Hypoxic-

- ischemic encephalopathy: a review for the clinician. *JAMA Pediatr.* 2015;169(4):397-403.
26. Vannucci RC. Hypoxic-ischemic encephalopathy. *AmJPerinatol.* 2000;17(3):113-20.
27. Mercuri E, Cowan F, Rutherford M, Acolet D, Pennock J, Dubowitz L. Ischaemic and haemorrhagic brain lesions in newborns with seizures and normal Apgar scores. *Arch Dis Child Fetal Neonatal Ed.* 1995;73(2):F67-74.
28. American Institute of Ultrasound in Medicine, American College of Radiology, Society of Radiologists in Ultrasound. AIUM practice guideline for the performance of neurosonography in neonates and infants. *J Ultrasound Med.* 2014;33(6):1103-10.

Copyright © 2022 The Authors. Published by Shahid Beheshti University of Medical Sciences.

This work is published as an open access article distributed under the terms of the Creative Commons Attribution 4.0 License

(<http://creativecommons.org/licenses/by-nc/4>). Non-commercial uses of the work are permitted, provided the original work is properly cited.
